



PATIENT

Cooper French

SPECIES

Canine

BREED

Shih Tzu

SEX

Male Neutered

AGE

13 years

WEIGHT

15.75lbs

INTERPRETED BY

Maggie Machen
Lamy, DVM
DACVIM (Cardiology)

**IMAGING
PERFORMED BY**

Pamela Harrigan,
RDCS

HOSPITAL NAME

Mass Veterinary
Specialty Services

REFERRING VET

Dr. Masloski

INVOICE

21615

DATE

10/20/21

PRESENTING CLINICAL SIGNS

History: Recheck echo. History chronic valvular disease - Stage B1. Current presentation: Cooper is overall slowing down a bit but still active. Good appetite. CV/RESP: NSR, grade IV/VI murmur with PMI left apical area radiating to right, PSS, lung fields clear. BP: >300 mmHg (stressed). No medications. *No sedation for study.
-Pertinent previous echo findings (3/16/21 MML): LA 1.7 cm; LA:Ao 1.3; LV 2.46 cm; mild LAE; moderate MR; mild TR (2.1 m/s).

ECHOCARDIOGRAM FINDINGS

2D, m-mode, color flow and Doppler imaging is available.

Left ventricle: The LV diameter is borderline with adequate myocardial function. LV wall thicknesses are normal.

Left atrium: The left atrium is mildly dilated.

Mitral valve: The mitral valve is diffusely thickened with mild prolapse into the left atrial lumen. Moderate eccentric mitral regurgitation with a normal velocity.

Aortic valve/aorta: The aortic valve is normal in morphology and mobility. Normal aortic outflow velocity; laminar flow. No aortic insufficiency.

Right ventricle: Normal right ventricular diameter and morphology indicating no overt evidence of pulmonary arterial hypertension.

Right atrium: Normal RA dimension.

Tricuspid valve: The tricuspid valve appears mildly thickened with mild tricuspid regurgitation; normal velocity.

Pulmonic valve/pulmonary artery: The pulmonic valve is normal in morphology and mobility. No pulmonic insufficiency. Normal RVOT velocity; laminar flow.

Pericardium/other: No pericardial or pleural effusion noted. No obvious cardiac masses.

Heart rhythm: ECG reveals a sinus rhythm with an average HR of 110bpm.

2-Dimensional Measurements

Ao diam (cm)	1.3
LA diam (cm)	1.7
LA:Ao (Swe)	1.3
IVS thickness (cm)	0.56
LVID diastole (cm)	2.5
PW thickness (cm)	0.59
LVID systole (cm)	1.3
FS (%)	48

Doppler Measurements

PV Vmax (m/s)	0.55
AoV Vmax (m/s)	1.4
MR Vmax (m/s)	6.1
TR Vmax (m/s)	2.4
TR PG (mmHg)	22

INTERPRETATION OF THE FINDINGS

Unchanged chronic degenerative valve disease is identified without evidence of progression. Moderate mitral and mild tricuspid regurgitation are unchanged and the left heart dimensions are stable. No concurrent issues are noted in this study.

Continued assessment of progression in the future will help predict long term prognosis, which is highly variable at this stage (B1).

The reported blood pressure is markedly elevated, and should be reassessed for accuracy particularly given no reported clinical signs of severe hypertension (retinal changes, etc) or evidence of LVH on echo. Ideally obtain serial measurements in a controlled, low stress environment and continue until 3 consecutive readings plateau within 5mmHg of



PATIENT
Cooper French

SPECIES
Canine

BREED
Shih Tzu

SEX
Male Neutered

AGE
13 years

WEIGHT
15.75lbs

INTERPRETED BY
Maggie Machen
Lamy, DVM
DACVIM (Cardiology)

**IMAGING
PERFORMED BY**
Pamela Harrigan,
RDCS

HOSPITAL NAME
Mass Veterinary
Specialty Services

REFERRING VET
Dr. Masloski

INVOICE
21615

DATE
10/20/21

variability. If persistently >180mmHg despite a relatively calm demeanor, recommend institution of amlodipine to effect. Additionally if deemed accurate, screening for predisposing underlying causes of SHT is recommended (Cushings, PLN, adrenal tumor, etc), as primary disease is relatively uncommon and a rule out diagnosis.

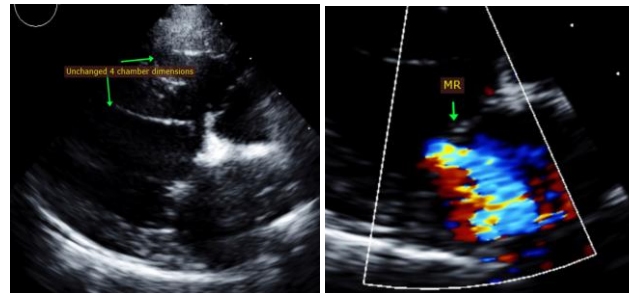
RECOMMENDATIONS

- Given these findings, no cardiac medications are clearly indicated.
- Reassess BP as discussed.
- Omega fatty acid supplementation and mild salt restriction may be of some long-term benefit.
- Anesthetic risk is considered mild if needed. Cardiac protective drug choices (opioid/benzodiazepine premedication, propofol or alfaxalone induction, isoflurane gas) are recommended. Pre-oxygenate for 5-10 minutes prior to induction. Monitor for arrhythmias, hypotension, and hypoxia both intra and post-operatively and intervene as necessary. Mild IV fluid restriction is recommended to avoid fluid overload. Avoid heart rate stimulating drugs such as atropine unless clinically indicated.
- Monitor for development of a cough, labored breathing, exercise intolerance or collapse episodes.

PLAN

- Recommend conservative monitoring with a recheck echocardiogram in 6-12 months, sooner if any development of clinical signs.

IMAGES



The information and recommendations provided are based on the images presented by the referring veterinarian. No evaluation can be communicated regarding pathology that was not visible in the image/video clips provided.

Thank you for this referral. This report was generated using transcription software, and minor dictation errors may be present. If the clinical or image interpretation does not parallel your findings or if I can be of any further assistance, please contact me.

Maggie Machen Lamy, DVM
Diplomate of the American College of Veterinary Internal Medicine (Cardiology)
info@sonopath.com

Echocardiogram performed by: Pamela Harrigan, RDCS
Pet Animal Ultrasound Service (4paus.com)